



REVIEW ARTICLE

Optimizing prehospital care: a comprehensive review of evidence-based protocols for tension pneumothorax management

Abdullah Alsamhari*^{ORCID}, Rafiulla Gilkaramenthi^{ORCID}, Bader Hussain Alamer^{ORCID},
Albaraa Jebreel^{ORCID}, Hamdi Hasan Abdulbari, Saad M. Mushawwah^{ORCID},
and Lara Altaezi^{ORCID}

Department of Emergency Medical Services, College of Applied Sciences, AlMaarefa University,
Diriyah 13713, Riyadh, Kingdom of Saudi Arabia

* Correspondence Author:

 Asamhari@um.edu.sa

Date of first submission, March 5, 2025

Date of final revised submission, April 24, 2025

Date of acceptance, April 29, 2025

Cite this article as: Alsamhari A, Gilkaramethi R, Alamer BH, et al.

Optimizing prehospital care: a comprehensive review of evidence-based protocols for tension pneumothorax management. *Univ Med* 2025;44:113-128

ABSTRACT

It is of the utmost importance to diagnose and treat tension pneumothorax (TPX) as soon as possible, because if not recognized and treated, it may swiftly cause collapse of the respiratory and circulatory systems. An estimated 5% of people with serious thoracic injuries may die from this avoidable cause, making it a leading cause of death in trauma and prehospital situations. Methods for diagnosis, procedures for intervention, and strategies for training are the primary foci of this study, which aims to provide a synthesis of evidence-based protocols for the prehospital treatment of TPX. A literature search was done on Pubmed and Google Scholars databases to identify the relevant literature from 2015 to 2025. This review focuses on the use of point-of-care ultrasonography to improve diagnosis accuracy and assesses the effectiveness of needle decompression and finger thoracostomy as first-line therapies. We will go over the main research that back these methods, how they differ between regions, and the difficulties of implementing them in prehospital care. Standardized training methods and further studies on appropriate intervention strategies are two of the significant gaps in the literature that are pointed out in this review. These results provide suggestions for improving prehospital care, increasing survival rates, and enhancing clinical practice. This review highlights current evidence-based strategies for diagnosing and managing tension pneumothorax (TPX) in prehospital settings. It emphasizes advancements such as point-of-care ultrasound (POCUS) and interventions such as needle decompression and finger thoracostomy. The review also addresses challenges in protocol implementation, especially in developing EMS systems such as in Saudi Arabia, citing issues such as training disparities, limited resources, and system readiness.

Keywords: Tension pneumothorax, emergency medical services, POCUS, pleural decompression, cardiac arrest

INTRODUCTION

Tension pneumothorax (TPX) is a life-threatening condition in which air accumulates in the pleural cavity, leading to increased

intrathoracic pressure and compression of vital thoracic structures.⁽¹⁾ This results in reduced venous return, decreased cardiac output, and ultimately hemodynamic collapse. As one of the leading causes of preventable deaths in trauma

cases, tension pneumothorax demands urgent recognition and immediate intervention in prehospital and emergency settings. Delayed or inadequate management can lead to fatal outcomes, underscoring the critical importance of standardized, evidence-based treatment protocols.⁽²⁾ Emergency medical services (EMS) clinicians frequently encounter traumatic pneumothorax, which can be categorized as either simple or tension pneumothorax. While simple pneumothorax has a minimal impact on hemodynamics, TPX disrupts blood flow, induces shock, and significantly increases the risk of severe complications and mortality.⁽³⁾ Needle thoracostomy (NT), a widely used EMS intervention, has life-saving potential but is often performed incorrectly or with suboptimal success rates in decompressing a tension pneumothorax. As a result, concerns have emerged regarding its effectiveness, leading to growing interest in alternative techniques such as simple thoracostomy (ST) or tube thoracostomy.⁽⁴⁾ Emergency medical services providers are responsible for determining the need for pleural decompression and ensuring that the procedure is performed both safely and effectively. Additionally, the management of open pneumothorax in prehospital settings remains an area of uncertainty, further emphasizing the necessity of well-defined protocols.⁽⁵⁾

This review aims to evaluate and synthesize current evidence-based approaches to TPX diagnosis and management in prehospital settings. In particular, it highlights advancements in diagnostic techniques, including point-of-care ultrasound (POCUS), as well as therapeutic interventions such as needle decompression and finger thoracostomy. Furthermore, it explores the challenges associated with implementing these protocols in diverse healthcare systems, with a focus on developing EMS infrastructure, such as in Saudi Arabia. Variability in training, resource availability, and system preparedness further complicate the effective management of this potentially fatal medical emergency. By addressing these gaps, this review seeks to contribute to the development of standardized evidence-based guidelines that optimize prehospital care and improve patient outcomes.⁽⁶⁾

METHODS

A comprehensive literature search was conducted using PubMed and Google Scholar to

identify relevant English-language studies published between 2015 and 2025. The search strategy employed Boolean operators, combining key terms such as "Tension Pneumothorax" AND "Emergency Medical Services" AND ("Needle Decompression" OR "Thoracostomy" OR "Finger Thoracostomy") AND ("Prehospital Management" OR "Management Protocols") AND "Flail Chest". Studies were screened based on predefined inclusion and exclusion criteria. Inclusion criteria consist of studies focusing on prehospital management of tension pneumothorax, specifically discussing diagnostic approaches, intervention techniques, and EMS protocols. Only peer-reviewed original research, systematic reviews, and meta-analyses were considered. Exclusion criteria include non-English studies, case reports, editorials, and studies lacking prehospital context (Figure 1). Two independent researchers extracted the data, and any discrepancies were resolved through discussion with a third reviewer. The methodological quality of the included studies were assessed using the Newcastle-Ottawa Scale (NOS) for observational studies and the Cochrane Risk of Bias Tool for randomized controlled trials. A narrative synthesis was used to interpret the findings, and a systematic method was applied to determine the quantitative effectiveness of data on different management protocols. (Table 1).

Diagnosis and treatment approaches

Emergency medical services physicians should focus on fast recognition of tension pneumothorax while avoiding the attempt to detect each simple pneumothorax. The prehospital zone requires precise diagnosis to determine when treating tension pneumothorax early will offer more benefits than performing senseless pleural decompression procedures.^(4,5) The data reveals that between 18% and 42% of patients who received emergency medical services' prehospital pleural decompression showed no pneumothorax presence in their CT scans performed at the emergency department.^(6,7)

The traumatic force necessary to produce pneumothorax normally occurs in severe impacts and tends to appear together with multiple visceral injuries when blunt chest trauma occurs.⁽⁸⁾ When safety belts and airbags activate during car crashes, they minimize both severe thoracic wounds and prevent most cases of pleural decompression.⁽⁹⁾ The protective factors from vehicle safety equipment should be factored into

shock-related assessments by EMS for trauma patients with TPX.⁽¹⁰⁾

Direct ear listening to breath sounds proves valuable for diagnosing pneumothorax because decreased air noises in one lung have a diagnostic accuracy approaching 93–98% (86–97% PPV) for significant pneumothorax.⁽¹¹⁾ The accuracy of auscultation for detecting pneumothorax is limited because it detects breath sounds poorly in noisy environments or when patients receive bronchial intubation, therefore leading to false interpretation of pneumothorax as being an issue with asymmetric breath sounds.⁽¹²⁾ A diagnosis of alternative conditions that cause unilateral breath sound decreases, such as gastrothorax, becomes

harder to discern in clinical settings (Table 1). Medical professionals encounter increased difficulties when dealing with TPX recognition especially during cases of bilateral pneumothorax.⁽¹³⁾

The clinical indication of tachypnea serves as an important diagnostic sign, yet healthcare providers often fail to detect it, leading to poor thoracic trauma screening outcomes.⁽¹⁴⁾ The assessment becomes difficult when ventilators are used since healthcare providers must evaluate spontaneous respiratory effort.⁽¹⁵⁾ Doctors can use symmetric breath sounds together with regular respiratory rate and no dyspnea to eliminate pneumothorax as the diagnosis.⁽¹⁶⁾

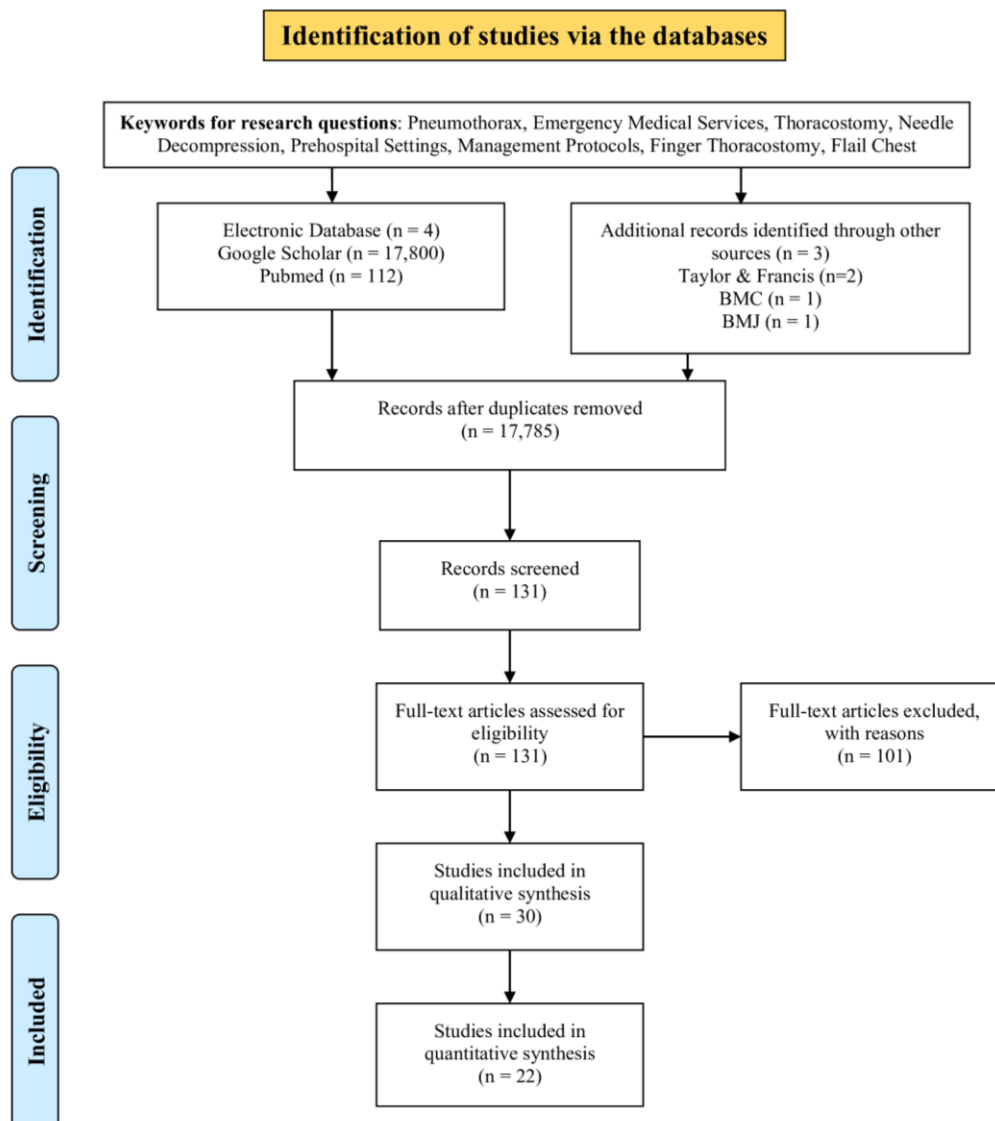


Figure 1. Searching process for literature findings

Table 1. Clinical signs and symptoms of tension pneumothorax in patients on positive pressure ventilation and those breathing spontaneously ⁽²²⁾

| Symptom or examination findings | Positive pressure ventilation | Spontaneous breathing |
|---|-------------------------------|--|
| Respiratory symptoms | | |
| Chest pain | Not applicable | 50–100% |
| Dyspnea or respiratory distress | <10% | 40–100% |
| Tachypnea | Not applicable | >45% |
| Hypoxia | >90% | |
| Cyanosis | 75% of advanced TPX | <10% |
| Pulmonary examination findings | | |
| Ipsilateral decreased air entry/breath sounds | 30–50% | 90% of advanced TPX |
| Hyperresonance | <10% | 30–45% |
| Subcutaneous emphysema | 20–30% | 100% of advanced TPX |
| Contralateral tracheal deviation | <10% | <25% (late finding in 60% of advanced TPX) |
| Ipsilateral thoracic hyper-expansion | 33% | <15% |
| Cardiovascular findings | | |
| Jugular venous distension | <20% | <15% |
| Hypotension (MAP <60mmHg) | >45% | <25% (80% of advanced TPX) |
| Tachycardia | 30–45% | 30–75% (95% of advanced TPX) |
| Neurological symptoms | | |
| Altered mentation | Not applicable | <10% |
| Ventilation and progression indicators | | |
| High ventilation pressure | 33% | Not applicable |
| Rapid onset and decline | 25–50% | |
| Sudden onset | 30–100% | <15% |
| Progressive onset | <15% | 30–45% |
| Severe complications | | |
| Respiratory arrest | Not applicable | <15% |
| Cardiac arrest | 30–45% | <15% |

Field assessment should include point-of-care ultrasonography (POCUS) due to its growing recommendation in clinical practice.⁽¹⁷⁾ Standard chest X-rays prove less accurate than POCUS in diagnosis, but in-flight POCUS performed by EMS demonstrates poorer results than emergency department testing. Successful diagnosis of pneumothorax depends heavily on an expert operator's skills. AI systems integrated with real-time POCUS image transmission processes to expert reviewers enhance diagnostic accuracy broadly.⁽¹⁸⁾ A pneumothorax diagnosis through POCUS does not necessitate pleural decompression, since a small pneumothorax of 18 mL can be detected, while a silent pneumothorax can have volumes up to 378 mL. Trained operators who implement quality assurance procedures demonstrate the potential of EMS-POCUS to reduce ineffective treatments.^(19,20)

Tension pneumothorax displays different clinical symptoms between patients under positive pressure ventilation (PPV) versus those who

breathe on their own.^(21,22) Research by Roberts et al. and by Gottlieb and Long established that mechanical ventilation places patients at much higher risk of hypotension combined with cardiac arrest compared to spontaneously breathing patients, based on their measurements of 12.6-fold increased early hypotension risk and 17.7-fold greater adjusted mortality rate.^(23,24) The use of PPV ventilation on pneumothorax patients leads to the development of subcutaneous emphysema as one of its complications. Due to the influence of ventilation status, both tracheal deviation signs and jugular venous distension may be either overemphasized or disappear completely, which highlights the necessity for detailed evaluation when treating patients in the prehospital setting.⁽²⁵⁾

Objective observations in the presence of shock of unknown etiology, abrupt loss of cardiac output, traumatic arrest, or other similar conditions, warrant the recommendation of pleural decompression by EMS doctors.⁽²⁶⁾ Clinicians from the emergency medical services should

refrain from decompressing patients who are hemodynamically stable for uncomplicated pneumothorax. Figure 2 provides additional standards to direct decision-making about pleural decompression.⁽²⁷⁾

Needle thoracostomy

Although NT is done in 0.03% of pediatric trauma cases, it is the most frequent decompression procedure used by EMS doctors,⁽²⁸⁻³⁰⁾ accounting for up to 5% of trauma cases overall. When done properly, NT may reduce the risk of death within 24 hours by as much as 25%. However, up to 30–94% of NT insertions are either misplaced or do not succeed in penetrating the pleural region.^(31,32) Additionally, 12–42% of EMS NTs are done for no good reason (Figure 3). Improving the accuracy of TPX diagnosis and the frequency of procedural success are two areas that restrict the clinical value of NT in the present EMS environment.⁽³³⁾

Risk of iatrogenic injury and complications from needle thoracostomy

Intrathoracic vascular injuries, myocardial perforation, diaphragmatic damage, liver and spleen lacerations, and other iatrogenic

complications may develop as a result of NT. It is also feasible to create iatrogenic pneumothorax by doing NT on individuals who are mistakenly diagnosed with pneumothorax.⁽³⁴⁾ For individuals with genuine TPX, a portion of this risk is tolerable. Nevertheless, there is substantial cause for worry over the potential of serious harms without benefit in the 42% of patients who have unnecessary prehospital NT.⁽³⁵⁾

Some have cast doubt on EMS professionals' capacity to correctly pinpoint NT prescribed sites. Correctly locating the lateral NT site, which is the 4th or 5th intercostal space (ICS) at the anterior axillary line (4/5 ICS anterior axillary line [AAL]), is more challenging for military clinicians than the anterior NT site, which is the 2nd intercostal space midclavicular line (2 ICS midclavicular line [MCL]).^(36,37) The accuracy with which civilian paramedics pinpoint the frontal position varies as well; 28% get it within 2 cm, while 86% get it within 5 cm. Studies have shown that between 20% and 40% of NTs are placed incorrectly (Figure 3), such as outside of the 2 ICS or 1-2 cm too far from the medial collateral ligament (MCL), proving that physicians are not perfect.^(38,39)

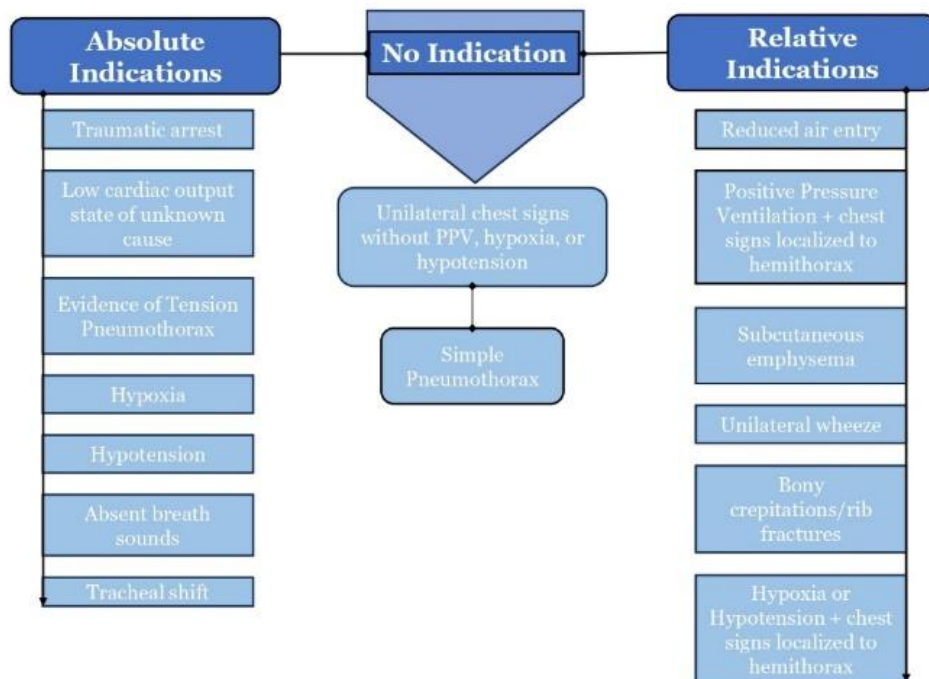


Figure 2. Indications for prehospital thoracostomy by London helicopter emergency medical services (EMS)⁽²⁷⁾

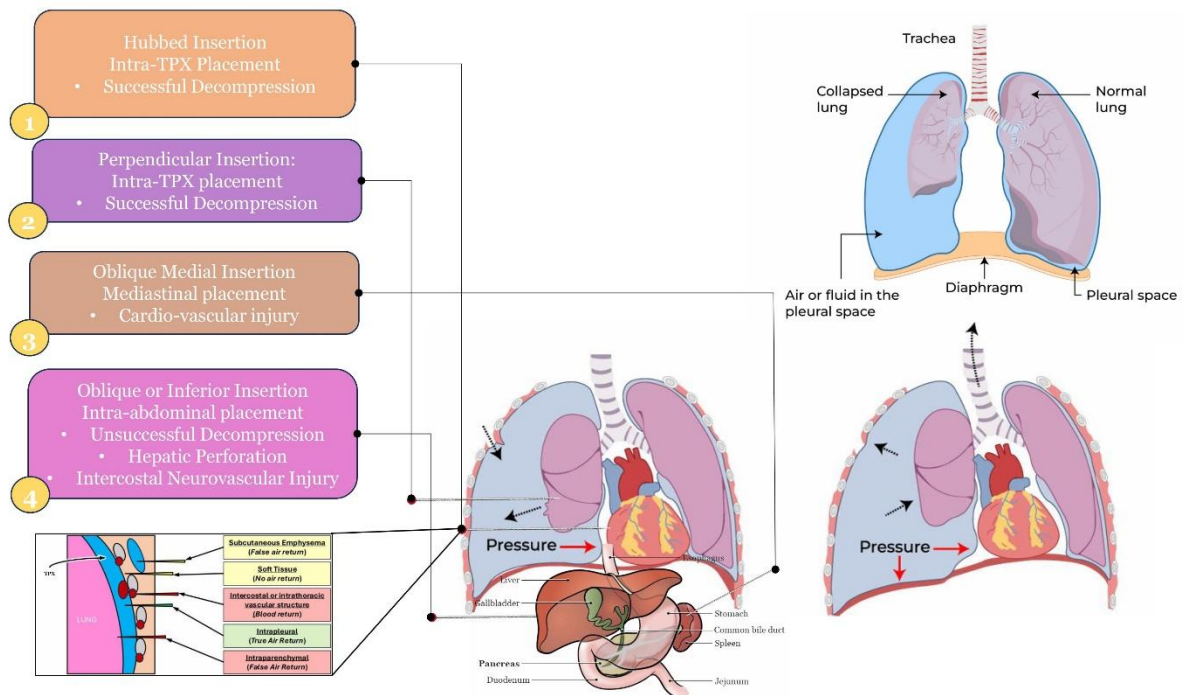


Figure 3. Potential iatrogenic injuries related to needle thoracostomy based on insertion angle and anatomical location. This serves as a stepwise guide for detecting and managing suspected tension pneumothorax (27,67,95,96)

A number of factors, including the patient's age, the method of insertion, the length of the device, and the anatomic location, influence the risk of iatrogenic damage and ineffective decompression with NT.^(40,41) Left lateral approaches for NT have a high risk of cardiac damage across all age groups. It is important to implant the NT device as near to the superior border of the rib as feasible to minimize harm to the intercostal arteries, which may be worsened by the elderly's increased vascular tortuosity and by the smaller ICS in juvenile patients.^(42, 43) Needles shorter than 6 cm would not be able to pass through an adult's chest wall, according to many studies. Devices longer than 7 cm have been linked to a greater risk of iatrogenic damage without boosting the effectiveness of decompression, even though several publications suggest using NT devices between 5 and 8 cm. Injuries caused by medical interventions are more likely to occur in pediatric patients when NT devices longer than 3.8 cm are utilized.^(44,45)

Anatomic factors related to successful needle thoracostomy

Although various studies have proposed optimal anatomical sites for anterior or lateral needle thoracostomy (NT), a universal “one-site-fits-all” approach fails to account for critical

patient-specific variables.⁽⁴⁶⁾ Factors such as chest wall thickness (CWT), proximity of vulnerable anatomical structures, patient posture, and device characteristics all significantly influence NT success. In adult females, the anterior chest wall is generally thicker than in males, while lateral CWT differences are less pronounced.⁽⁴⁷⁾ However, in individuals with a body mass index (BMI) ≤ 30 kg/m²—typically aged 18–40—these differences tend to diminish. Postural variation also plays a role; raising the arms overhead can notably reduce CWT, potentially improving procedural accuracy.⁽⁴⁸⁾

For lateral NT, site identification can be complicated in females due to anterior breast tissue, which may obscure critical landmarks. Similarly, physiological changes during pregnancy—such as diaphragmatic elevation and displacement of abdominal organs—necessitate upward adjustment of the needle insertion site from the 4th to the 3rd intercostal space (ICS) to avoid inadvertent injury to intra-abdominal structures.⁽⁴⁹⁾

Age and sex further influence CWT and thus NT efficacy. Studies show that a 4.5 cm catheter may be insufficient for effective pleural decompression in 10% of males under 40 and 19% of males over 40.⁽⁵⁰⁾ The risk is even higher in females, affecting 33% of women under 40 and

25% of those over 40. Conversely, anterior NT has shown higher success rates in both sexes aged over 75, likely due to naturally thinner CWT.⁽⁵¹⁾ Additionally, patients with chronic obstructive pulmonary disease (COPD) typically exhibit thinner CWTs, which may increase NT success despite age-based expectations.⁽⁵²⁾ In pediatric populations (under 13 years), anatomical consistency leads to fewer challenges in pleural access, with body weight emerging as the most reliable predictor of CWT.^(53,54) Based on this, Battaloglu and Porter⁽⁵⁶⁾ recommend a 3.8 cm, 14- or 16-gauge NT catheter for children in this age group or those fitting a length-based resuscitation tape. Importantly, the standard 5 cm over-the-needle catheter advised by Advanced Trauma Life Support (ATLS) for adults significantly exceeds the average pediatric CWT.

Multiple retrospective analyses have also examined the relationship between BMI and CWT. While both anterior and lateral sites show increased CWT with rising BMI, the anterior site is most significantly affected. The likelihood of unsuccessful pleural access escalates with BMI: 25% in underweight, 46% in normal-weight, 78% in overweight, and 92.9% in obese individuals.^(55, 57) These findings underscore the importance of a tailored approach to NT—taking into account anatomical variation, BMI, age, sex, and underlying health conditions to optimize patient outcomes and procedural success.⁽⁵⁸⁾

Device characteristics necessary for successful needle thoracostomy

The standard for NT devices in adults is 6.5 cm, but children should not have one longer than 3.8 cm, according to current research.⁽⁵⁹⁾ A common concern with flexible NT catheters is the possibility of kinking or occlusion, particularly during lateral NT procedures when the patient's arm is compressed against the catheter. Stiff NT devices have been created to lessen the effects of kinking,⁽⁶⁰⁾ but inflexible instruments with sharp tips pose a threat of injury to interior organs and tissues. One solution to this problem is the use of blunt tips on various NT devices, such as Veress needles. These tips retract to expose the sharp tip, which incises the chest wall. Once the needle reaches the pleural cavity, the blunt tips extend to hide them.⁽⁶¹⁾ We found an article from Kirmse and Paxton⁽⁶¹⁾ that addressed the question of whether or not these device changes increase the risk of iatrogenic damage from NT, despite the fact that other studies describe similar devices.

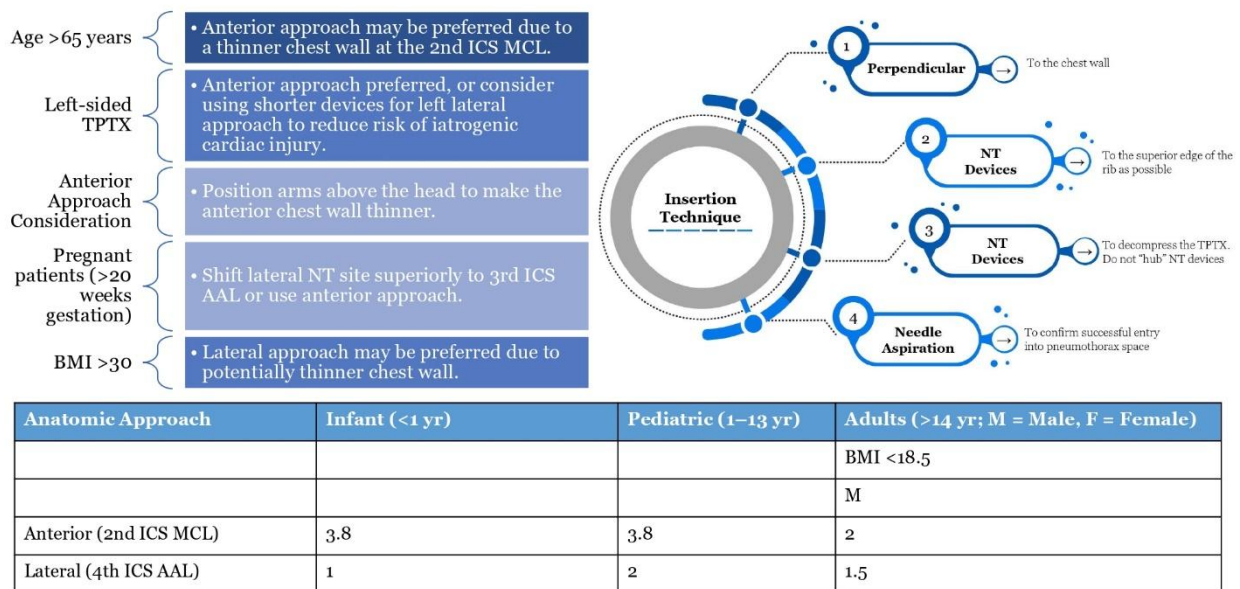
Needle thoracostomy technique

Radiographic evaluation of CWT, taking method into account, may exaggerate the true success of NT.⁽⁶²⁾ Minimizing the CWT that must be crossed and perhaps reducing the risk of iatrogenic damage may be achieved with perpendicular insertion, as shown in tactical combat casualty care (TCCC) suggesting that the over-the-needle catheter be placed by "hubbing the needle" (withdrawing the needle while holding the catheter still), on a regular basis to avoid unsuccessful pleural decompression because of a CWT that is longer than the NT device.⁽⁶³⁾ Having NT devices longer than 7 cm may raise the risk of iatrogenic harm, although "hubbing" can be risky. It is important to note that TCCC recommendations are designed to guide the treatment of young, healthy troops and may not apply to civilians.⁽⁶⁴⁾

In an EMS context, we may use one of several NT verification methods. In order to decompress TPX safely and reliably, EMS personnel may utilize POCUS to find the necessary depth and then confirm that decompression was effective. This has been shown in EMS settings including pediatric patients. Despite descriptions of this method in hospital settings, pilot trials evaluating its efficacy in people have been few.⁽⁶⁵⁾ To minimize the danger of harm to deeper tissues, NT may be performed using a needle aspiration approach, which involves attaching a saline-filled syringe to the NT device (Figure 4). This technique helps restrict the depth to which the needle penetrates. Additional study is necessary to validate the practicality of needle aspiration and POCUS-guided NT in the emergency medical services context, despite their potential as approaches to confirm effective NT and decrease the likelihood of iatrogenic damage. The EMS worker should collect all the patient-, device-, and technique-related considerations for the most effective and safe pleural cavity access possible.⁽⁶⁶⁾

Simple thoracostomy and tube thoracostomy

Most studies related to simple thoracostomy (also known as finger or open thoracostomy) emerge from EMS physicians' practice settings in Australia together with selected European countries. The translation of study conclusions for simple thoracostomy into prehospital care administered by paramedics in the United States needs careful examination.⁽⁶⁷⁾



Footnote: ICS = Intercostal Space; MCL = Midclavicular Line; AAL = Anterior Axillary Line

Figure 4. Overview of device specifications and technique adjustments to enhance needle thoracostomy safety and effectiveness based on patient factors ⁽⁵⁰⁾

Emergency services in EDs choose ST as their preferred method for pleural decompression since it shows greater reliability than NT.⁽⁶⁷⁾ However, the evidence available for prehospital settings does not provide solid proof that ST shows better clinical results than NT. Ambulance crews face a technical challenge with ST, because medical complications include iatrogenic injuries, failure to access the pleural cavity, and missed or recurrent pneumothorax in about 10.6% of cases.⁽⁶⁸⁾

Medical facility EDs show comparable tube thoracostomy (TT) complication rates when compared to physician-based EMS systems according to available data. Medical professionals who perform ST achieve better success rates along with fewer complications in comparison to NT.⁽⁶⁹⁾ ST's implementation as an ordinary procedure for EMS clinicians needs thorough evaluation of its technical requirements and resource needs. Compelling quality control systems must exist for ST procedures to maintain safety and effectiveness during delivery.⁽⁷⁰⁾

The most advanced thoracostomy procedure called TT possesses greater complexity than other procedures but has associated hazards. Studies found that EMS physicians in helicopter emergency medical services achieve 75% clinical improvement rates, but must handle TT-related

misplacements reaching 22% rates among patients.⁽⁷¹⁾ Research demonstrates that EMS personnel achieve complication rates from thoracostomy procedures which match those obtained by hospital-based doctors. The utilization of trocar-based techniques during hospital-based TT procedures leads to malposition of organs or severe injuries in about thirty percent of cases. The use of trocar methods leads to 30% of incidents where intrabdominal placement occurs incorrectly.⁽⁷²⁾

The risk of injury during EMS-performed TT becomes lower when trocars with sharp tips get eliminated from use. Medical personnel should use digital examination first for pleural cavity entry verification through manual intercostal tissue dissection to avoid iatrogenic injuries.⁽⁷³⁾ Accomplishment levels required to perform ultrasound-guided TT interventions are higher but it offers EMS practitioners the advantage of enhanced procedural precision and reduced health risks during field interventions.⁽⁷⁴⁾

In pediatric cases, particularly those involving children under 10 years of age, NT presents notable limitations. Quinn et al.⁽⁷⁵⁾ reported a 30% failure rate of prehospital NT in pediatric patients with tension pneumothorax (TPX) and advocated for TT in this population. However, due to anatomical constraints—such as

a typically narrow (<1 cm) fourth intercostal space—introducing a finger into the pleural cavity during ST or TT carries significant risk of damaging intercostal nerves and vessels.⁽⁷⁶⁾ As a result, ST is generally contraindicated in this age group. Instrument-based transthoracic ultrasound remains the safer alternative for pleural decompression in pediatric patients under 10 years old.⁽⁷⁷⁾ When adopting traumatic thoracostomy, EMS systems need to budget for dedicated training as well as resources and equipment needed for safe practice on both adult and pediatric patients.^(77,78)

Confirming successful pleural decompression

There are a number of potential indicators of success, such as the presence of an improvement in vital signs, a "rush of air" auditory impression, or compliance with ventilation. Air may be discharged from causes other than a pneumothorax, therefore relying on an initial "rush of air" to establish adequate NT insertion is not a reliable strategy.⁽⁷⁹⁾ If TPX is the only cause of acute shock, then the vital signs should recover when decompression is effective. Decompression of TPX may not improve vital signs if it occurs with hemorrhagic, neurogenic, cardiogenic, or other forms of obstructive shock.⁽⁸⁰⁾ There is commercially available equipment that can visually demonstrate the insertion of an NT device into the pleural space by chemical or mechanical processes; however, these tools have not been extensively tested on people. The greatest real-time proof that the pleural space has been accessed is provided by simple thoracostomy and TT procedures that use digital evaluation.⁽⁸¹⁾ It has been reported that both TT and ST may be misplaced into the chest wall, and that decompression can be partial or fail altogether.⁽⁸²⁾ Instead of digitally exploring the chest cavity, other approaches may employ commercial equipment or trocars to dissect through the chest wall, which might lead to some misdirected ST or TT.⁽⁸³⁾

Need for downstream intervention

If NT is done, Bosman et al.⁽⁸⁴⁾ say to perform a final TT in the emergency department. In hemodynamically stable patients, choices to do ST or TT after NT should be based on radiographic evidence of genuine pneumothorax, since EMS NTs are performed at a high rate of needless procedures and fail at a high rate of entering the pleural space.

Depending on the EMS clinician's area of practice, patients who are hemodynamically unstable and have already had NT should undergo either repeat NT or a ST or TT. To confirm that the ST entered the pleural space correctly and that the site has not been blocked, patients who are hemodynamically unstable and have had ST should have a repeat finger sweep. Patients who are unstable should be evaluated for potential causes of traumatic shock. The Royal College of Surgeons suggests reusing the ST incision for TT instead of creating a new one, even though there is no published evidence to direct practitioners to do so. This lessens the likelihood of subsequent issues and cuts out needless incisions. Despite the lack of evidence, all definitive TT implantation after field-based STs should be followed by intravenous antibiotic administration in the emergency department.⁽⁸⁵⁾

Suspected tension pneumothorax in traumatic out-of-hospital cardiac arrest

Trauma patients who are unstable but have vital signs are the best candidates for needle thoracostomy.⁽⁸⁶⁾ Decommission is a potentially life-saving procedure for instances of traumatic out-of-hospital cardiac arrest (TOHCA) resulting from isolated TPX. Both the frequency of TPX as a cause of TOHCA and the effect of decompression on return of spontaneous circulation (ROSC) and overall survival vary substantially between situations. The percentage of TOHCA with TPX in the Netherlands was 9.7%. A third of the TOHCA patients in one ground-based US EMS system tested positive for TPX.⁽⁸⁷⁾ Up to 60% of the deaths in U.S. civilian public mass casualty shooting incidents were caused by avoidable pneumothorax, according to Smith et al.⁽⁸⁶⁾ Since traumatic epidemiology may vary in air-based and foreign EMS systems, and since EMS doctors often play a bigger role in delivering in-field treatment in these settings, it is difficult to extrapolate results to EMS systems in the United States.⁽⁸⁷⁾

Among a total of 37 TOHCAs, after 17 cases received ST from EMS doctors and 1 case received NT from paramedics, ROSC was found in 4 out of the 18 cases (22.2%). Outward symptoms of chest damage were absent in all four ROSC patients despite the presence of TPX symptoms.⁽⁸⁸⁾ Within 24 hours after obtaining ROSC, all of these patients succumbed to non-survivable brain injuries. In a larger study, six of 909 TOHCAs (0.7%) treated with bilateral ST by

London HEMS EMS doctors were able to achieve ROSC. Paramedics in Houston, TX, studied 57 patients who had blunt TOHCA (75% bilateral STs). The results indicated a rate of ROSC of over 25% and a neurologically intact survival rate of 7% (4/57).⁽⁸⁸⁾ Paramedics in California conducted an observational analysis on 169 TOHCAs with bilateral NT and found no difference in fatality rates between piercing and blunt traumatic causes. With careful use of field-performed TT, a German study of 757 patients undergoing TOHCA increased survival.⁽⁸⁸⁾ Lastly, it was shown that using trauma-based resuscitation techniques does improve the incidence of EMS thoracostomy in TOHCA, but it does not enhance ROSC or survival to discharge. According to this evidence, if EMS patients have TOHCA and show symptoms of TPX, they should undergo NT or ST.⁽⁸⁸⁾ However, routine empiric bilateral decompression is not recommended unless there is suspicion of TPX from thoraco-abdominal trauma; doing so is unlikely to increase survival rates.⁽⁸⁹⁾

Prophylactic pleural decompression and open pneumothorax

Many trauma victims get transported by first aid medical services as a main service while Helicopter Emergency Medical Services (HEMS) plays the most significant role. Medical personnel need to perform tube thoracostomy decompression of pneumothorax before transport in any patient with either confirmed or suspected simple pneumothorax using radiographic imaging. The safety of patients depends on immediate pneumothorax treatment because altitude changes could expand the pneumothorax yet make it harder to detect and manage a TPX.⁽⁹⁰⁾

The research by Weichenthal et al.⁽⁹⁰⁾ shows that pneumothorax patients on positive pressure ventilation can unpredictably develop TPX during air transport largely because many HEMS patients get PPV. The extra 53 minutes needed to perform decompression before HEMS transfer does not reduce survival benefits which seem to appear when patients receive TT pre-flight, during flight or with ground transport only. The survival advantages from TT treatment remain unexplained since they could derive from both the TT technique or the potential advantages of faster HEMS transfers.

Physiological research shows that a pneumothorax tends to expand 12.7–16.2% when patients remain at 5,000 feet above sea level. The

formation of TPX presents as a rare occurrence during aerial transport even though the group is made up of PPV patients. Researchers tracked 66 adult patients under HEMS transportation at 18,900 feet on average and discovered transient ischemic chest pain in only four patients while three of 14 patients with PPV developed TPX that was correctly diagnosed and treated through needle thoracostomy mid-flight.⁽⁹¹⁾

Among 412 pediatric trauma patients who achieved an average altitude rise of 2,337 feet through air transportation there were no cases of TPX identified.⁽⁹²⁾ The subject group included 77.4% of patients who already presented with pneumothorax before being transferred. TT interventions after arrival in the trauma center involved 19 patients, with fifteen patients having undergone PPV during transport because medical staff exercised caution instead of demonstrating TPX development. Alqudah et al.'s data mirrored the findings when evaluating PPV patients under HEMS transfer by showing no cases of TPX. The evidence indicates emergency thoracotomy should not be required for standard low-altitude helicopter transfers.⁽⁹¹⁾

The critical level of open pneumothorax management depends on how well the patients can breathe by themselves. Patients who breathe independently experience negative intrathoracic pressure that produces a suction effect which causes surrounding air to flow through their chest wound thus worsening their condition.⁽⁹³⁾ Air intrusion through an open pneumothorax can be prevented through the strategic use of chest seals. PPV under artificial ventilation creates positive intrathoracic pressure that reduces the minimal chances of chest air entry. Open-chest ventilation therapy makes chest seals an ineffective treatment approach which actually increases the risk of TPX and so these seals are unsuitable for mechanically ventilated patients.⁽⁹⁴⁾

Blood accumulation along with non-vented dressings has the potential to create TPX as a medical condition. It is essential to check for TPX symptoms so any covering dressing needs removal in case these symptoms appear. Unsuccessful treatment calls for immediately performing NT or ST. The evidence about chest seal efficiency remains unclear but vented commercial seals prove more effective than unvented counterparts.⁽⁹⁴⁾ When chest seals are unavailable medical staff should use a thin dry adhesive dressing instead, although 3-sided dressings have been discontinued from usage. Real-life conditions

present the risk that blood and debris can interfere with the proper adherence of chest seals. Every EMS team must evaluate using chest seals based on their individual clinical requirements of their local area.⁽⁹⁵⁾

Medical personnel should never insert any element into a chest wound when treating open pneumothorax and tension pneumothorax simultaneously particularly when the pleural decompression occurs at standard positions. The use of chest seals requires an inspection to determine whether their presence is creating obstruction; if this occurs, then the seal must be removed. When patient compromise continues after chest seal application for open pneumothorax treatment the provider must use needle or serrated tube thoracostomy to decompress the damaged pleural space at a suitable site on the same side. Medical providers need to evaluate contralateral thoracic pneumatosis when the damage to mediastinal structures requires treatment. When these stabilizing measures do not work the EMS provider needs to check for alternative shock-inducing conditions.⁽⁹⁶⁾

Implementation guidance and evaluation

Emergency medical technicians have the ability to save lives by decompressing TPX, and NT is likely the most cost-effective and straightforward method to use in this situation. It is unfortunate that NT is often done ineffectively or without need. Mechanisms to guarantee initial and continuous competence are crucial, considering the limitations of detecting TPX and the rarity of an individual EMS clinician performing NT. There were no definitive findings on the most effective methods of instruction; however, cadaver or manikin-based practical training could be superior than classroom instruction alone. The high price tag of these resources could prevent their widespread use.⁽⁹⁴⁾

At the present time, only paramedics, nurses, and EMS doctors are authorized to provide NT, which means that only the areas covered by these professionals may access it. Expanding the area of practice for advanced emergency medical technicians (EMTs) or emergency medical responders (EMRs) is not suitable until there are improvements in EMS TPX detection and NT performance.⁽⁹⁴⁾

Revisions to curriculum should place an emphasis on rapid assessment of the clinical efficacy of pleural decompression and precise in-field identification of TPX in order to enhance

results. Among other important topics, revisions should underline how TPX manifests differently in individuals who are ventilated compared to those who are breathing on their own. More progress might be made if field-appropriate, inexpensive equipment could be developed to enhance TPX detection, certify effective decompression in real-time, and/or reduce procedural risk. Additional study is necessary to establish the efficacy of POCUS in additional EMS situations, despite its promising results in managing TPX in the HEMS scenario. Procuring equipment, training physicians, and performing quality assurance to ensure that POCUS programs fulfill objectives, would need considerable expenditure. If there are future supporting data, there may be greater use of POCUS for TPX.⁽⁹⁴⁾

Last but not least, additional funding should be allocated to quality assurance in order to track and assess clinical performance, as well as the impact of EMS interventions on patient-based outcomes. These outcomes include topics such as effective thoracostomy interventions, accurate recognition of TPX, surveillance for complications related to thoracostomy, and other measures of morbidity and mortality.⁽⁹⁶⁾

CONCLUSION

Emergency medical technicians have the ability to significantly reduce the occurrence of potentially fatal conditions, including open pneumothorax and traumatic tension pneumothorax (TPX), by identifying and treating patients in a timely manner. If we want the best possible results for our patients, we must ensure that EMS providers can correctly recognize these emergencies. For this reason, it is crucial to work on enhancing EMS education, evaluation methods, and intervention plans. Training should prioritize the quick clinical evaluation of TPX, with a focus on differentiating between patients who are ventilated and those who are breathing on their own. To further improve treatment quality, dependable measures for confirming effective pleural decompression should be used, such as point-of-care ultrasonography (POCUS) or real-time verification approaches. Improving patient outcomes requires quality supervision and ongoing assessment of clinical performance, which includes proper thoracostomy intervention, precise detection of TPX, and monitoring for consequences. Investment in cost-effective, field-appropriate equipment to enhance TPX

identification and decrease procedural hazards should also be considered by EMS services. Additional research is necessary to fill in evidence gaps, especially in studies that directly include EMS, and to take into consideration differences in the scope of practice for clinicians, even if the measures stated in this paper provide practical actions for EMS organizations. Emergency medical services may significantly enhance patient care and results by using these tactics.

Acknowledgement

The authors would like to express their gratitude to the Department of Emergency Medical Services at AlMaarefa University for their invaluable contribution and support throughout this study.

Author Contributions

AA: Supervised the data collection process, and checked writing, approved methodology, manuscript editing, and supervised all steps, including final editing; RG: Researched literature, web-survey design, coordinated and monitored the data collection process with collaborators, wrote the first draft of the manuscript; SMM, LA: Paper revision; HHA: Interpreted data, checked writing; AJ: Manuscript editing; BHA: Final editing, reviewing, and supervising the steps. All authors have read and approved the final manuscript

Conflict of Interest

None.

Funding

None.

Data Availability Statement

None.

Declaration the Use of AI in Scientific Writing

Yes, but only for language modification.

REFERENCES

1. Cantwell K, Burgess S, Patrick I, et al. Improvement in the prehospital recognition of tension pneumothorax: the effect of a change to paramedic guidelines and education. *Injury* 2014;45:71-6. doi: 10.1016/j.injury.2013.06.010.
2. Sharrock MK, Shannon B, Garcia Gonzalez C, et al. Prehospital paramedic pleural decompression: a systematic review. *Injury* 2021;52:2778-86. doi: 10.1016/j.injury.2021.08.008.

3. Lesperance RN, Carroll CM, Aden JK, Young JB, Nunez TC. Failure rate of prehospital needle decompression for tension pneumothorax in trauma patients. *Am Surg*. 2018;84:1750–5. doi:10.1177/000313481808401130.
4. Neeki MM, Cheung C, Dong F, et al. Emergent needle thoracostomy in prehospital trauma patients: a review of procedural execution through computed tomography scans. *Trauma Surg Acute Care Open* 2021;6:e000752. doi:10.1136/tsaco-2021-000752.
5. Robitaille-Fortin M, Norman S, Archer T, Mercier E. Prehospital decompression of pneumothorax: a systematic review of recent evidence. *Prehosp Disaster Med* 2021;36:450–9. doi:10.1017/S1049023X21000509.
6. Di Bartolomeo S, Sanson G, Nardi G, Scian F, Michelutto V, Lattuada L. A population-based study on pneumothorax in severely traumatized patients. *J Trauma* 2001;51:677–82. doi:10.1097/00005373-200110000-00009.
7. Smith ER, Sarani B, Shapiro G, et al. Incidence and cause of potentially preventable death after civilian public mass shooting in the US. *J Am Coll Surg* 2019;229:244–51. doi:10.1016/j.jamcollsurg.2019.04.016.
8. Leech, C, Porter, K, Steyn, R, et al. The pre-hospital management of life-threatening chest injuries: a consensus statement from the Faculty of Pre-Hospital Care, Royal College of Surgeons of Edinburgh. *Trauma* 2016;19:54–62. doi:10.1177/1460408616664553.
9. Peters J, Ketelaars R, van Wageningen B, Biert J, Hoogerwerf N. Prehospital thoracostomy in patients with traumatic circulatory arrest: results from a physician-staffed helicopter emergency medical service. *Eur J Emerg Med* 2017;24:96–100. doi:10.1097/MEJ.0000000000000337.
10. Paul S, Ahmed T, Kumer A, et al. A survey-based study on seasonal diseases & treatment pattern during winter in Narayananj City. *Int J Biosci* 2023;22:132-8. doi:10.12692/ijb/22.1.132-138.
11. Roberts DJ, Leigh-Smith S, Faris PD, et al. Clinical presentation of patients with tension pneumothorax: a systematic review. *Ann Surg* 2015;261:1068-78. doi: 10.1097/SLA.0000000000001073.
12. Wickramasinghe S, Ruggiero B, Low L. Gastrothorax: a case of mistaken identity. *Int J Surg Case Rep*. 2018;44:66-69. doi: 10.1016/j.ijscr.2018.02.022.
13. Phelan J, Subramanian R, Menon AKK. Acute atraumatic peri-arrest tension gastrothorax presenting to the emergency department. *BMJ Case Rep* 2021;14: e240478. doi: 10.1136/bcr-2020-240478.
14. Wernick B, Hon HH, Mubang RN, et al. Complications of needle thoracostomy: a comprehensive clinical review. *Int J Crit Illn Inj*

- Sci 2015;5:160–9. doi:10.4103/2229-5151.164939.
15. Huan NC, Sidhu C, Thomas R. Pneumothorax: classification and etiology. *Clin Chest Med* 2021;42:711–27. doi: 10.1016/j.ccm.2021.08.007.
 16. Yonge JD, Bohan PK, Watson JJ, Connelly CR, Eastes L, Schreiber MA. The respiratory rate: a neglected triage tool for pre-hospital identification of trauma patients. *World J Surg*. 2018;42:1321–6. doi: 10.1007/s00268-017-4353-4.
 17. Robitaille-Fortin M, Norman S, Archer T, Mercier E. Prehospital decompression of pneumothorax: a systematic review of recent evidence. *Prehosp Disaster Med* 2021;36:450–9. doi: 10.1017/S1049023X21000509.
 18. Alrajhi K, Woo MY, Vaillancourt C. Test characteristics of ultrasonography for the detection of pneumothorax: a systematic review and meta-analysis. *Chest* 2012;141:703–8. doi: 10.1378/chest.11-0131.
 19. Griffiths E. Helicopter emergency medical services use of thoracic point of care ultrasound for pneumothorax: a systematic review and meta-analysis. *Scand J Trauma Resusc Emerg Med* 2021;29:163. doi: 10.1186/s13049-021-00977-0.
 20. Ronaldson J, Moultrie CEJ, Corfield AR, McElhinney E. Can non-physician advanced retrieval practitioners (ARP) acquire and interpret diagnostic views of the lungs with sufficient quality to aid in the diagnosis of pneumothorax in the pre-hospital and retrieval environment? *Scand J Trauma Resusc Emerg Med* 2020;28:102. doi: 10.1186/s13049-020-00797-8.
 21. Kim K, Macruz F, Wu D, et al. Point-of-care AI-assisted stepwise ultrasound pneumothorax diagnosis. *Phys Med Biol* 2023;68:205013. doi:10.1088/1361-6560/acfb70.
 22. Gilday C, Odunayo A, Hespel AM. Spontaneous pneumothorax: management and prognosis. *Top Companion Anim Med* 2021;45:100582. doi: 10.1016/j.tcam.2021.100582.
 23. Holland HK, Holena DN. Moving the needle on early mortality after injury – a role for liberalizing prehospital needle decompression? *JAMA Surg* 2022;157:941. doi: 10.1001/jamasurg.2022.3561.
 24. Gottlieb M, Long B. Managing spontaneous pneumothorax. *Ann Emerg Med* 2023;81:568–76. doi: 10.1016/j.annemergmed.2022.08.447.
 25. Pierce JD, Shah NR, Rahnemai-Azar AA, Gupta A. Non-traumatic tension gastrothorax: a potential mimicker of tension pneumothorax. *J Radiol Case Rep* 2021;15:1–7. doi: 10.3941/jrcr.v15i8.4144.
 26. High K, Brywczynski J, Guillaumondegui O. Safety and efficacy of thoracostomy in the air medical environment. *Air Med J* 2016;35:227–30. doi:10.1016/j.amj.2016.04.002.
 27. Laher AE, Buchanan SK. Mechanically ventilating the severe asthmatic. *J Intensive Care Med* 2018;33:491–501. doi: 10.1177/0885066617740079.
 28. Tran J, Haussner W, Shah K. Traumatic Pneumothorax: a review of current diagnostic practices and evolving management. *J Emerg Med* 2021;61:517–28. doi: 10.1016/j.jemermed.2021.07.006.
 29. Muchnok D, Vargo A, Deeb AP, Guyette FX, Brown JB. Association of prehospital needle decompression with mortality among injured patients requiring emergency chest decompression. *JAMA Surg* 2022;157:934–40. doi: 10.1001/jamasurg.2022.3552.
 30. Warner KJ, Copass MK, Bulger EM. Paramedic use of needle thoracostomy in the prehospital environment. *Prehosp Emerg Car* 2008;12:162–8. doi: 10.1080/10903120801907299.
 31. Dominguez KM, Ekeh AP, Tchorz KM, et al. Is routine tube thoracostomy necessary after prehospital needle decompression for tension pneumothorax? *Am J Surg* 2013;205:329–32. doi:10.1016/j.amjsurg.2013.01.004.
 32. Robitaille-Fortin M, Norman S, Archer T, Mercier E. Prehospital decompression of pneumothorax: a systematic review of recent evidence. *Prehosp Disaster Med* 2021;36:450–9. doi: 10.1017/S1049023X21000509.
 33. Beck, B, Smith, K, Mercier, E, et al. Potentially preventable trauma deaths: a retrospective review. *Injury* 2019;50:1009–16. doi: 10.1016/j.injury.2019.03.003.
 34. Leech C, Porter K, Steyn R, et al. The pre-hospital management of life-threatening chest injuries: a consensus statement from the Faculty of Pre-Hospital Care, Royal College of Surgeons of Edinburgh. *Trauma* 2017;19:54–62. doi:10.1177/1460408616664553.
 35. Lee SK, Seo KH, Kim YJ, et al. Cardiac arrest caused by contralateral tension pneumothorax during one-lung ventilation: a case report. *Anesth Pain Med (Seoul)* 2020;15:78–82. doi: 10.17085/apm.2020.15.1.78.
 36. Wernick B, Hon HH, Mubang RN, et al. Complications of needle thoracostomy: a comprehensive clinical review. *Int J Crit Illn Inj Sci*. 2015;5:160–9. doi: 10.4103/2229-5151.164939.
 37. Lubin JS, Knapp J, Kettenmann ML, Knapp JM, Kettenmann M. Paramedic understanding of tension pneumothorax and needle thoracostomy (NT) site selection. *Cureus* 2022;14:e27013. doi: 10.7759/cureus.27013.
 38. Mendogni P, Vannucci J, Ghisalberti M, et al. Collaborators of the Pneumothorax Working Group, on behalf of the Italian Society for Thoracic Surgery (endorsed by the Italian Ministry of Health) Collaborators of the

- Pneumothorax Working Group; D'Ambrosio AE, De Vico A, Guerrera F, Imbriglio G, Pardolesi A, Schiavon M, Russo E. Epidemiology and management of primary spontaneous pneumothorax: a systematic review. *Interact Cardiovasc Thorac Surg* 2020;30:337-45. doi: 10.1093/icvts/ivz290.
39. Hohenberger GM, Schwarz A, Hohenberger F, et al. Evaluation of Monaldi's approach with regard to needle decompression of the tension pneumothorax – a cadaver study. *Injury*.2017;48:1888–94. doi:10.1016/j.injury.2017.06.001.
40. Chang SJ, Ross SW, Kiefer DJ, et al. Evaluation of 8.0-cm needle at the fourth anterior axillary line for needle chest decompression of tension pneumothorax. *J Trauma Acute Care Surg* 2014;76:1029–34. doi:10.1097/TA.000000000000158.
41. Tschopp JM, Bintlcliffe O, Astoul P, et al. ERS task force statement: diagnosis and treatment of primary spontaneous pneumothorax. *Eur Respir J* 2015;46:321-35. doi: 10.1183/09031936.00219214.
42. Terboven T, Leonhard G, Wessel L, et al. Chest wall thickness and depth to vital structures in paediatric patients – implications for prehospital needle decompression of tension pneumothorax. *Scand J Trauma Resusc Emerg Med* 2019;27:45. doi:10.1186/s13049-019-0623-5.
43. Arshad H, Young M, Adurty R, Singh AC. Acute pneumothorax. *Crit Care Nurs Q* 2016;39:176-89. doi: 10.1097/CNQ.000000000000110.
44. Thomas A, Wilkinson KH, Young K, Lenz T, Theobald J. Complications from needle thoracostomy: penetration of the myocardium. *Prehosp Emerg Care* 2021;25:438–40. doi:10.1080/10903127.2020.1772419.
45. Laan DV, Vu TDN, Thiels CA, Pandian TK, et al. Chest wall thickness and decompression failure: a systematic review and meta-analysis comparing anatomic locations in needle thoracostomy. *Injury* 2016;47:797–804. doi:10.1016/j.injury.2015.11.045.
46. Chan KK, Joo DA, McRae AD, et al. Chest ultrasonography versus supine chest radiography for diagnosis of pneumothorax in trauma patients in the emergency department. *Cochrane Database Syst Rev* 2020;7:CD013031. doi: 10.1002/14651858.CD013031.pub2.
47. Aragaki-Nakahodo A. Management of pneumothorax: an update. *Curr Opin Pulm Med*. 2022;28::62-67. doi: 10.1097/MCP.0000000000000839.
48. Akoglu H, Akoglu EU, Evman S, et al. Determination of the appropriate catheter length and place for needle thoracostomy by using computed tomography scans of pneumothorax patients. *Injury* 2013;44:1177–82. doi:10.1016/j.injury.2012.10.005.
49. Jain V, Chari R, Maslovitz S, et al. Guidelines for the management of a pregnant trauma patient. *J Obstet Gynaecol Can*. 2015;37:553–74. doi:10.1016/s1701-2163(15)30232-2.
50. Thompson P, Ciaraglia A, Handspiker E, et al. Risk of harm in needle decompression for tension pneumothorax. *J Spec Oper Med* 2023;23:9–12. doi:10.55460/ZU1D-3DL9.
51. Rizzo A, Martin M, Inaba K, et al. Pregnancy in trauma – a Western Trauma Association algorithm. *J Trauma Acute Care Surg* 2022;93:e139–e42. doi:10.1097/TA.0000000000003740.
52. Hossain R, Qadri U, Dembowski N, et al. Sound and air: ultrasonographic measurements of pediatric chest wall thickness and implications for needle decompression of tension Pneumothorax. *Pediatr Emerg Care*. 2021;37:e1544–8. doi:10.1097/PEC.0000000000002112.
53. Schroeder E, Valdez C, Krauthamer A, et al. Average chest wall thickness at two anatomic locations in trauma patients. *Injury* 2013;44:1183–5. doi:10.1016/j.injury.2013.03.027.
54. Goh S, Xu W, Teo L. Decompression of tension pneumothoraces in Asian trauma patients: greater success with lateral approach and longer catheter lengths based on computed tomography chest wall measurements. *Eur J Trauma Emerg Surg*. 2018;44:767–71. doi:10.1007/s00068-017-0853-z.
55. Inaba K, Ives C, McClure K, et al. Radiologic evaluation of alternative sites for needle decompression of tension pneumothorax. *Arch Surg* 2012;147:813–8. doi:10.1001/archsurg.2012.751.
56. Battaloglu E, Porter K. Management of pregnancy and obstetric complications in prehospital trauma care: faculty of prehospital care consensus guidelines. *Emerg Med J* 2017;34:318–25. doi:10.1136/emermed-2016-205978.
57. Powers WF, Clancy TV, Adams A, West TC, Kotwall CA, Hope WW. Proper catheter selection for needle thoracostomy: a height and weight-based criteria. *Injury*. 2014;45:107–11. doi:10.1016/j.injury.2013.08.026
58. Carter TE, Mortensen CD, Kaistha S, Conrad C, Dogbey G. Needle decompression in appalachia do obese patients need longer needles? *West J Emerg Med* 2013;14:650–2. doi:10.5811/westjem.2013.7.15844.
59. Paquette R, Quinene M, Blackbourne LH, Allen PB. Efficacy of commercial chest seal adherence and tension pneumothorax prevention: a systematic review of quantitative studies. *J Spec Oper Med* 2021;21:78-85. doi: 10.55460/FZ33-7RLL.

60. Rathinam S, Grobler S, Bleetman A, Kink T, Steyn R. Evolved design makes ThoraQuik safe and user friendly in the management of pneumothorax and pleural effusion. *Emerg Med J* 2014;31:59–64. doi:10.1136/emmermed-2012-201821.
61. Kirmse AJ, Paxton JH. Devices used in the treatment of tension pneumothorax. *Curr Emerg Hosp Med Rep* 2023;11:151–7. doi:10.1007/s40138-023-00272-5.
62. Butler FK, Holcomb JB, Shackelford SA, et al. Management of suspected tension pneumothorax in tactical combat casualty care: TCCC guidelines change 17-02. *J Spec Oper Med* 2018;18:19–35. doi:10.55460/XB1Z-3BJU.
63. Dewar ZE, Ko S, Rogers C, Oropallo A, Augustine A, Pamula A, Berry CL. Prehospital portable ultrasound for safe and accurate prehospital needle thoracostomy: a pilot educational study. *Ultrasound J* 2022;14:23. doi:10.1186/s13089-022-00270-w.
64. Mayer N, Dalal P. POCUS-guided assessment and drainage of pleural effusion. In: *Cardiopulmonary point of care ultrasound*. Cham: Springer International Publishing; 2023. pp. 343–54.
65. Nelson M, Chavda Y, Stankard B, McCann-Pineo M, Nello A, Jersey A. Using ultrasound to determine optimal location for needle decompression of tension pneumothorax: a pilot study. *J Emerg Med* 2022;63:528–32. doi:10.1016/j.jemermed.2022.08.004.
66. Maxwell WB. The hanging drop to locate the pleural space: a safer method for decompression of suspected tension pneumothorax? *J Trauma* 2010;69:970–1. doi:10.1097/TA.0b013e3181f2a24a.
67. Damps-Konstańska I, Szukalska A, Janowiak P, Jassem E. Catamenial pneumothorax-still an unveiled disease. *Medicina (Kaunas)* 2024;60:2029. doi:10.3390/medicina60122029.
68. Jodie P, Kerstin H. BET1: pre-hospital finger thoracostomy in patients with traumatic cardiac arrest. *Emerg Med J* 2017;34:417–8. doi:10.1136/emmermed-2017-206808.1.
69. Mohrsen S, McMahon N, Corfield A, McKee S. Complications associated with pre-hospital open thoracostomies: a rapid review. *Scand J Trauma Resusc Emerg Med*. 2021;29:166. doi:10.1186/s13049-021-00976-1.
70. Halifax R, Janssen JP. Pneumothorax - time for new guidelines? *Semin Respir Crit Care Med* 2019;40:314–22. doi:10.1055/s-0039-1693499.
71. Struck MF, Leclair N, Wrigge H. Bilateral false-positive tube thoracostomy in helicopter emergency medical service. *Air Med J* 2015;34:4. doi:10.1016/j.amj.2014.09.006.
72. Harrell KN, Brooks DE, Palm PH, Cowart JT, Maxwell R, Barker D. A comparison of prehospital nonphysician and hospital physician placed tube thoracostomy. *Am Surg*. 2020;86:841–7. doi:10.1177/0003134820940238.
73. Bouzat P, Raux M, David JS, et al. Chest trauma: first 48hours management. *Anaesth Crit Care Pain Med* 2017;36:135–45. doi:10.1016/j.accpm.2017.01.003.
74. Rath T, Imdahl A. Das kann ein spontaner „Pneu“ sein! [Pneumothorax]. *MMW Fortschr Med* 2018;160:48-50. German. doi:10.1007/s15006-018-0434-z.
75. Quinn N, Palmer CS, Bernard S, Noonan M, Teague WJ. Thoracostomy in children with severe trauma: an overview of the paediatric experience in Victoria, Australia. *Emerg Med Australas* 2020;32:117–26. doi:10.1111/1742-6723.13392.
76. Thachuthara-George J. Pneumothorax in patients with respiratory failure in ICU. *J Thorac Dis* 2021;13:5195-204. doi:10.21037/jtd-19-3752.
77. Menegozzo CAM, Utiyama EM. Steering the wheel towards the standard of care: proposal of a step-by-step ultrasound-guided emergency chest tube drainage and literature review. *Int J Surg* 2018;56:315–9. doi:10.1016/j.ijsu.2018.07.002.
78. Alvarez M, Evans DD, Tucker P. Spontaneous pneumothorax: controversies in treatment. *Adv Emerg Nurs J* 2023;45:169-76. doi:10.1097/TME.0000000000000465.
79. Musa J, Zielinski M, Hernandez M, et al. Tension pneumothorax decompression with colorimetric capnography: pilot case series. *Gen Thorac Cardiovasc Surg* 2022;70:59–63. doi:10.1007/s11748-021-01686-2.
80. Zietlow J, Hernandez M, Bestland A, et al. Decompression of tension pneumothorax in a trauma patient – first use of a novel decompression colorimetric capnography device in human patient. *Gen Thorac Cardiovasc Surg* 2021;69:391–3. doi:10.1007/s11748-020-01471-7.
81. Drumheller BC, Basel A, Adnan S, et al. Comparison of a novel, endoscopic chest tube insertion technique versus the standard, open technique performed by novice users in a human cadaver model: a randomized, crossover, assessor-blinded study. *Scand J Trauma Resusc Emerg Med* 2018;26:110. doi:10.1186/s13049-018-0574-2.
82. Neeki MM, Cheung C, Dong F, et al. Emergent needle thoracostomy in prehospital trauma patients: a review of procedural execution through computed tomography scans. *Trauma Surg Acute Care Open* 2021;6:e000752. Chest t
83. Jouneau S, Vuillard C, Salé A, et al. Outpatient management of primary spontaneous pneumothorax. *Respir Med* 2021;176:106240. doi:10.1016/j.rmed.2020.106240.
84. Bosman A, de Jong MB, Debeij J, van den Broek PJ, Schipper IB. Systematic review and meta-

- analysis of antibiotic prophylaxis to prevent infections from chest drains in blunt and penetrating thoracic injuries. *Br J Surg* 2012;99:506–13. doi:10.1002/bjs.7744.
85. Heinänen M, Brinck T, Lefering R, Handolin L, Söderlund T. Resource use and clinical outcomes in blunt thoracic injury: a 10-year trauma registry comparison between southern Finland and Germany. *Eur J Trauma Emerg Surg* 2019;45: 585–95. doi:10.1007/s00068-018-1004-x.
86. Smith ER, Sarani B, Shapiro G, et al. Incidence and cause of potentially preventable death after civilian public mass shooting in the US. *J Am Coll Surg* 2019;229:244–51. doi:10.1016/j.jamcollsurg.2019.04.016.
87. Dickson RL, Gleisberg G, Aiken M, et al. Emergency medical services simple thoracostomy for traumatic cardiac arrest: postimplementation experience in a ground-based suburban/rural emergency medical services agency. *J Emerg Med* 2018;55:366–71. doi:10.1016/j.jemermed.2018.05.027.
88. Lyng JW, Ward C, Angelidis M, et al. Prehospital trauma compendium: traumatic pneumothorax care: position statement and resource document of NAEMSP. *Prehosp Emerg Care* 2024;1-21. doi: 10.1080/10903127.2024.2416978.
89. Scott RM, Henske EP, Raby B, Boone PM, Rusk RA, Marciniak SJ. Familial pneumothorax: towards precision medicine. *Thorax* 2018;73:270-6. doi: 10.1136/thoraxjnl-2017-211169.
90. Weichenthal LA, Owen S, Stroh G, Ramos J. Needle thoracostomy: does changing needle length and location change patient outcome? *Prehosp Disaster Med* 2018;3:237–44. doi:10.1017/S1049023X18000316.
91. Alqudah Z, Nehme Z, Williams B, Oteir A, Smith K. Survival outcomes in emergency medical services witnessed traumatic out-of-hospital cardiac arrest after the introduction of a trauma-based resuscitation protocol. *Resuscitation*. 2021; 168:65–74. doi:10.1016/j.resuscitation.2021.09.011.
92. Becher NA, Kierulf G, Bothwell S, Hills-Dunlap JL, Mandt M, Moulton SL. Interfacility transport of children with traumatic pneumothorax: does elevation make a difference? *J Pediatr Surg* 2024;59:316-9. doi: 10.1016/j.jpedsurg.2023.10.022.
93. Margolis AM, Tang N, Levy MJ, Callaway DW. Management of open chest wounds in tactical emergency casualty care: application of vented versus non-vented chest seals. *J Spec Oper Med* 2014;14:136–8. doi:10.55460/SGB8-4X9C.
94. Littlejohn LF. Treatment of thoracic trauma: lessons from the battlefield adapted to all austere environments. *Wilderness Environ Med* 2017; 28(2s):S69–S73. doi:10.1016/j.wem.2017.01.031.
95. Wernick B, Hon HH, Mubang RN, et al. Complications of needle thoracostomy: a comprehensive clinical review. *Int J Crit Illn Inj Sci* 2015;5:160–9. doi:10.4103/2229-5151.164939.
96. Chen KC, Chen PH, Chen JS. New options for pneumothorax management. *Expert Rev Respir Med* 2020;14:587-91. doi: 10.1080/17476348.2020.1740090.



This work is licensed under a Creative Commons Attribution-NonCommercial-ShareAlike 4.0 International License